

The Brachycephalic Syndrome

by Dr. Jan Grebe

Although written about the French Bulldog for Frenchie breeders and fanciers, every word in this excellent article equally applies to Bostons.

How many times have you heard of a French Bulldog who died young, suddenly, and without warning, with the death generally attributed to “a heart attack”? Such deaths, most often occurring when the dog is excited, being exercised, or hot, are all the more devastating because of their unexpectedness. True, the heart unquestionably stops beating, but could this be the result of death from another cause? A condition that may explain such deaths is an acute airway collapse, resulting from long-standing airway obstruction by the too-common French bulldog problems of stenotic nares, elongated soft palate, and crowded nasal passages and pharynx.

In order to understand this **brachycephalic syndrome** (a “syndrome” being a group of signs and symptoms that collectively characterize a disease or abnormal condition), we must first consider the normal mechanism of breathing, and how the abnormal construction of flat-faced dogs’ respiratory passages interferes with this mechanism.

Like humans, dogs “pull” air into their lungs by a process called “negative pressure breathing”. Instead of pumping air into the airway under positive pressure (which is what frogs do, by moving the floor of the mouth up and down and to “push” air down the airway), dogs (and we) expand the chest cavity by moving the ribs outward and the diaphragm downward. Since the chest cavity is a closed space, this expansion produces a partial vacuum, or space within which the air pressure is lower than that outside the body (“negative pressure”). Nature, which abhors even a partial vacuum, remedies this by allowing outside air to rush in through the nares, nasal cavities, pharynx, larynx and trachea, and finally via the bronchi and bronchioles into the air sacs of the lungs. This inflates the lungs, and the pressure in the chest cavity becomes equal to that of the outside air.

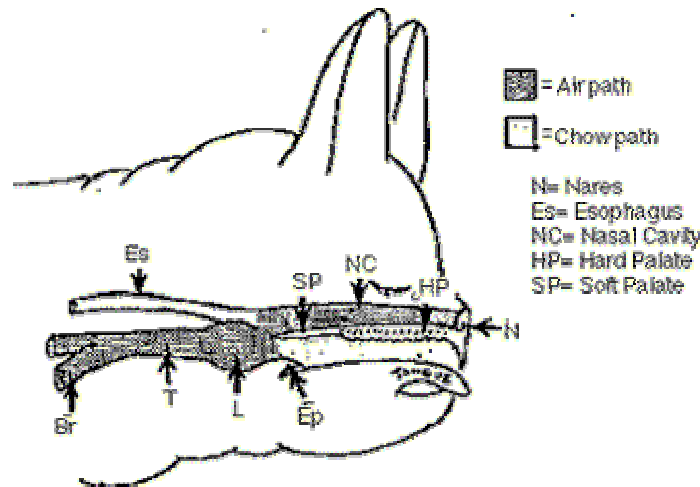
The problem is that while the Frenchie is inhaling air, there is a low pressure within the entire airway. This causes a “sucking” effect on the walls of those airway structures named above; **and the more vigorous the effort to inhale, the greater the forces that tend to pull the airway’s walls inward.**

Whether the dog is breathing hard because it’s hot, or exercising, or is simply excited, the stresses on the walls of the airway are the same. Most owners of flat-faced dogs are too aware of their tendency to overheat; that’s because most of the excess body heat is discharged through the lungs, and any respiratory impairment interferes with the heat loss process.

But few realize that the mere process of labored respiration for any reason, even without overheating, can cause progressive airway collapse that may eventually seriously impair or even kill a dog with chronic airway obstruction.

Figure 1 shows the different parts of the Frenchie airway. Consider first the nares. In some dogs, the nasal openings are big enough that air moves freely in and out. In others, they are stenotic (constricted or narrowed). Try forcibly inhaling air while being aware what your own nose is doing; notice how the sides of the nose cave in somewhat, as the forced inspiration pulls them inward? Now, try inhaling while pinching your nostrils shut; feel the “sucking inward” in your nasal cavities and throat? In a Frenchie with a small nasal opening, the sides of the nose act like flap-like valves that even a slight respiratory effort pulls tightly shut. You can see and hear the difference in breathing between a dog with open nares and one with stenotic ones. The harder the dog tries to

breathe, the more tightly the nares clamp shut, and the more the walls of the airway are pulled inward.



Once air gets through the nares into a short-faced dog's nasal cavities, it encounters more obstruction. Dogs with long muzzles have large nasal chambers with thin, curved bony shelves called turbinates projecting into the chambers from the sides. These structures help increase the surface area in the nasal cavities, increasing the nose's ability to cleanse and warm inhaled air. In a Frenchie, though, all of the internal nasal structures are squashed together in a variety of ways that may further impede air flow from nostrils to pharynx (throat). Thus, even if the nares are normal, crowded nasal cavities may obstruct air flow.

Moving down the airway, we next come to that bugaboo of flat-faced breeds, the **soft palate**, which separates the back end of the nasal cavity from the mouth cavity. Although some brachycephalic dogs have a soft palate that is short and in proportion to the abbreviated bony skull, many of them have an overly long soft palate that hangs far down into the pharynx (throat). This excessively large palate not only interferes with airflow from nasal chambers to throat, it can actually be drawn into the opening of the larynx. This may cause so much turbulence of airflow that the tissues of the palate become inflamed, thickened, and even more obstructive. One warning sign of an elongated soft palate is frequent gagging and frequent regurgitation of frothy saliva, usually not accompanied by vomiting of food. The elongated palate seems to act like an eggbeater, so that when the dog salivates, the palate whips the saliva into a froth, the dog gags, and up it comes — usually on the carpet (which is why some of us now have all wood floors with nary a carpet to be found anywhere in the house).

Elongated soft palate also usually produces some audible throaty sounds during breathing, alone or coupled with stenotic nares; this can result in some quite remarkable snoring and snorting. Endearing as this "Bully Nachtmusik" may be, it signals a real health problem.

From the nasal cavities, inhaled air moves through the **pharynx** and next down into the **larynx** (voicebox). Actually just the expanded and elaborated upper end of the trachea (windpipe), the box-like larynx consists of some cartilages apart or together so as to open or shut the **glottis**, the opening between the vocal cords that are attached to these cartilages. The **epiglottis** ('epi' meaning over), is a flap at the top of the larynx that folds down and covers the glottis during swallowing, so that the food doesn't enter the airway by mistake. People who try to talk and eat at the same time, often confuse the epiglottis, resulting in food's getting into the glottis and plugging up the airway; this is the so called 'cafe coronary' for which the *Heimlich Maneuver* is done.

If a dog gets a foreign body lodged in its glottis, completely blocking airflow, you can do the Heimlich Maneuver by placing the dog on its side, placing your palms at the last rib, and giving four sharp thrusts. Then check the mouth for the foreign body and repeat the procedure, if necessary. *Please note: this is only to be used for a complete airway blockage by a foreign object, at which time the heart will still be beating.*

It is *not indicated* for those awful gagging and snorting episodes with which we are all familiar, for those, the dog is best left alone. If the dog is able to snort, then its airway blockage is not complete, and you should not attempt Heimlich Maneuver. It's beyond our scope here to go into the procedure; if you aren't familiar with the Heimlich Maneuver, then we suggest you take a CPR course. This will cover the Maneuver as well as CPR, and the latter is also useful in the emergency resuscitation of pets as well as people.

When stenotic nares, elongated soft palate, or both cause chronic airway obstruction, the increased effort to pull air into the compromised airway exerts an ongoing stress on the walls of the larynx, in effect sucking them inward. This has two major effects:

First, it pulls inward on the **laryngeal ventricles (laryngeal sacculles)**; these little out pocketing of the thin membrane lining the larynx are located just above the vocal cords. Chronic airway obstruction *everts* these little membrane sacs, so instead of sticking outward, they are pulled inward and into the glottis, further clogging the already bad airway. Everted sacculles not only result from chronic airway obstruction, but also aggravate the problem.

Second, prolonged airway stress that pulls inward on the laryngeal walls can distort and collapse them inward, further obstructing the airway and increasing the effort necessary to inhale air. As with the palate, increased turbulence and vibrations in the airway cause swelling and irritation of the laryngeal membranes, further worsening the situation.

Third, the **trachea** in brachycephalic dogs may be underdeveloped ("hypoplastic"), and may present still another obstacle in breathing. If the trachea is abnormally narrow to start with, this not only contributes to the overall obstruction and helps increase the forces that are pulling inward on the airway walls, but also makes the trachea more easily collapsed. Partial collapse of the larynx or trachea may occur, increasing the respiratory effort, stress intolerance, and overheating problems.

Any or all of the above may persist for some time, without the owner's being aware that the airway's condition is becoming progressively worse due to the vicious cycle of *airway obstruction - airway changes - worse airway obstruction*. Then, unexpectedly, the dog may have a respiratory infection that causes some swelling, or gets excited, hot or exercised once too often. And suddenly the partially collapsed larynx or trachea may totally collapse, or the everted sacculles or soft palate may plug the glottis. The end result: *asphyxiation*, which unless the owner was aware of the problem, may be seen as "sudden death due to heart failure".

So what is to be done?

There are two issues to be dealt with: the life and health of *each individual dog*, and the life and health of the breed. First, consider the individual dog. Only one part of the airway (the nares) can be evaluated with anesthetizing the dog, since there's no way to look at the soft palate and larynx in a wide-awake Frenchie. Therefore, it's up to the owner to observe the dog with a high index of suspicion.

- Are the nares obviously stenotic? Can you see and hear them interfering with each intake of breath?
- Does the dog make a lot of “slobbery and gurgling” noises in the mouth and throat? Snore a lot? (I know, this is almost an “unofficial part” of the breed standard).
- Does the dog frequently gag or throw up froth, for no apparent reason?
- Does the dog’s breathing become easily labored even in cool weather, or with minimal exercise or stress?
- Does the dog overheat easily, even in moderate temperatures?

If you answer “yes” to any or all of these, your Frenchie may need further evaluation and, if indicated, surgery. A warning, though: some of the procedures used in treating this syndrome are not simple! If you have a vet with large Bulldog practice, she or he may have considerable experience with the brachycephalic syndrome, and may be perfectly competent to evaluate and treat your pet. If not, consider asking for referral either to a Vet School hospital, where there state-of-the art intensive facilities and specialists in surgery, anesthesia, and postoperative care.

If this is not available, talk to the English Bulldog people and ask who tends their dog’s airways. Many vets who feel they don’t have enough experience with brachycephalic syndrome will refer you to a colleague who has the necessary expertise. All Frenchie owners should have a good relationship with their vets, so that they can be frank about their concerns and their desire to obtain the very best available care for their pets, even if it means referral to another vet.

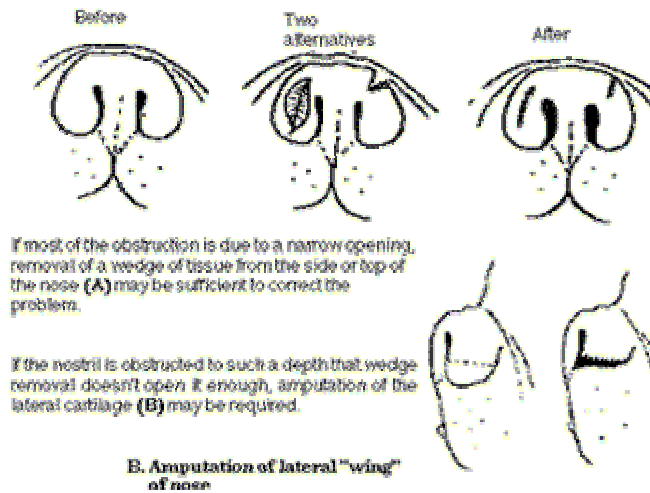
If it appears likely that there are serious airway problems, the vet must anesthetize the dog to evaluate it properly. The exam may be done under light anesthesia, but if the exam shows that surgery is needed, then the anesthesia can be deepened and the procedure done at the same time under the same anesthesia. Anesthesia carries risk for Frenchies in any event, and even more so when there is an airway problem; therefore it should be done as seldom as possible.

If the dog has stenotic nares, elongated soft palate, and everted laryngeal sacculles, all should be corrected at the same surgery. Bear in mind that the procedure on the nose will alter the appearance somewhat, this may cause a dilemma if you are showing the dog. However, if the nares are responsible for a significant proportion of the obstruction, then shortening the palate and removing the sacculles may not solve the problem, since the airway is only as good as its opening to the outside. If you are not showing the dog, then the minor change in the nose is a small price to pay for a healthier Frenchie.

In **shortening the palate** (a procedure called *staphylectomy*) the vet must take special precautions to maintain an open airway during and after surgery. First, of course, the dog should have an endotracheal tube inserted that is small enough to leave the surgeon enough room to work in the pharynx and larynx, but large enough to provide adequate air flow. Any manipulation of the larynx can very easily cause rapid swelling that is severe enough to close the airway. Therefore, a potent short-acting anti-inflammatory drug should be given at the start of the procedure to minimize swelling during surgery.

FIG. 2 shows three different procedures for opening the nares.

A. Wedge resection



After surgery, a long-acting anti-inflammatory is given to control swelling that may develop later. The dog should be kept sedated and not given food or water for 24 hours after surgery; fluids should be given intravenously to prevent dehydration. A drug may be given to reduce the amount of saliva that the dog secretes, to prevent choking. The endotracheal tube should not be removed until the dog is completely recovered from the anesthesia; and the patient should be kept resting on its belly as to keep its large tongue from relaxing and plugging up the throat. Close observation for a couple of days after surgery is really desirable, preferably by someone who is able to re-intubate the dog, or even do an emergency tracheostomy if necessary. (In a **tracheotomy**, a *temporary* opening is made through the front of the neck into the trachea, below the level of the larynx, and a tube is inserted here).

When the palate is shortened that it be shortened precisely the right amount. If too little is removed, it may still obstruct the airflow. If too much is cut off, not enough will be left to close off the airway during swallowing, and the dog will tend to aspirate food and water into its lungs. Bear in mind that there is no dotted line that shows the surgeon where to cut; and that if an error is made, it's better to cut off too little than too much. It's easier to trim off a little more tissue than to re-lengthen a too-short palate.

Removal of everted sacculles (laryngeal saccullectomy) is a brief procedure, usually done at the same time as the nares and/or palate are treated, and it involves snipping the sacculles out with scissors, or snaring them with a wire loop. It does not usually cause much bleeding, and it is much simpler than the palate shortening procedure. If the nares and soft palate are treated early enough, the sacculles may not yet have become everted, and correction of the other problems should prevent this happening.

If stenotic nares and/or elongated soft palate have lead to partial collapse of the larynx, then correction of the palate, nares and sacculles may prevent further laryngeal or tracheal collapse, and although some surgical procedures may help with certain cases, these are very complex, not always successful, and usually done only as a last resort. Some vets recommend a **tracheostomy** (*permanent* opening through the neck into the trachea) as the preferred treatment for acute laryngeal collapse. We will assume that Frenchie owners, once alerted to the problem, will have the nares and/or palate problems corrected *before* the collapse occurs.

A further suggestion: don't use any type of collar on a dog with any degree of airway impairment, to avoid putting any additional stress on the trachea. Even the most ox-like Frenchie neck may conceal a fragile airway, so a well-fitted harness is much better for the dog. And at least one Frenchie (who shall be nameless) has shown that a harness may even be used for obedience-training.

What about the significance of the brachycephalic syndrome for the Breed?

The root of the problem is the short face. Some genetic studies in the English Bulldog suggest that the gene that controls the lengths of the soft palate is a different one, from the gene that controls the length of the skull, and that the overlong palate is a souvenir of the breed's long-nosed ancestors. The root of the problem is the short face. Some genetic studies in the English Bulldog suggest that the gene that controls the lengths of the soft palate is a different one, from the gene that controls the length of the skull, and that the overlong palate is a souvenir of the breed's long-nosed ancestors.

If breeders would begin accumulating data about palate elongation in their lines, then when the GDCIS database is available, we can help determine whether this soft palate problem can be solved by selective breeding.

The problem is that the diagnosis requires anesthesia. Why not suggest that if any Frenchie must be anesthetized for any reason, like C-sections, minor surgery, spaying or neutering, the vet should examine the palate and the larynx at the same time? In this way, you may detect an unsuspected problem in time to prevent a serious laryngeal collapse, and also help accumulate data about the real frequency of airway problems in our breed.

If you feel that a Frenchie with a bad airway should be bred anyway, consider searching for a dog with a known good airway to breed to.

And don't condemn Frenchies with slightly longer noses. My first Frenchie whose "pet quality" status was determined by a nose a little longer than is considered desirable (despite a perfect body, superb ears, and a great gait), has enjoyed 9 years of good health and has never had a problem with overheating or exercise intolerance. And seldom even snores.

A French Bulldog's quality of life requires good breathing. If we all try to insure that each pup can lead an active life, and that airway problems in the breed as a whole become the exception instead of the norm, then we will all breathe easier – Frenchies and their owners alike.

© 1989 The French Bullytin. First published in The French Bullytin, Volume 7 No. 3, Summer 1989. Reprinted with permission from the author.